



ELSEVIER



<http://www.elsevier.com/locate/jiph>

SHORT REPORT

Probable case of spotted fever group rickettsial infection in a new suspected endemic area, Colombia



Carlos H. Gómez-Quintero^a, Álvaro A. Faccini-Martínez^{b,*},
Carlos A. Botero-García^c, Marcela Lozano^a,
Liliana Sánchez-Lerma^d, Jorge Miranda^e, Salim Mattar^e,
Marylin Hidalgo^f

^a Grupo de Enfermedades Infecciosas, Clínica De La Mujer, Bogotá, Colombia

^b Programa de Pós-Graduação em Doenças Infecciosas, Centro de Ciências da Saúde, Universidade Federal do Espírito Santo, Vitória, Brazil

^c School of Medicine, Universidad Militar Nueva Granada, Bogotá, Colombia

^d Facultad de Medicina, Universidad Cooperativa de Colombia, Villavicencio, Colombia

^e Instituto de Investigaciones Biológicas del Trópico, Montería, Colombia

^f Departamento de Microbiología, Pontificia Universidad Javeriana, Bogotá, Colombia

Received 15 June 2016; received in revised form 10 August 2016; accepted 19 August 2016

KEYWORDS

Rickettsia;
Rickettsia infections;
Spotted fever group;
Colombia

Summary Spotted fever group (SFG) rickettsioses are actually considered as emerging and re-emerging zoonotic diseases, caused by pathogenic bacteria of the spotted fever group rickettsiae (SFGR). Recently, serologic studies in human and animals conducted in Colombian Orinoquia, showed a high seroprevalence against SFGR. In June 2015, a 50-year-old male was admitted to a hospital in Bogotá, Colombia, with two days of malaise and temperature of 39 °C, associated to generalized rash 24 h after the onset of fever. He referred a work visit and outdoor activities in rural area of the Department of Meta 15 days prior the onset of symptoms. The patient was transferred to the intensive care unit with supplementary oxygen, inotropic support and was assessed by the infectious diseases department, indicating the addition of Doxycycline. After seven days of antibiotic treatment the patient was discharged with no evidence of new symptoms or sequels. Retrospectively, two serum samples collected during the acute and convalescent phase were evaluated; there was four fold rise in titer against SFGR. With the foregoing, associated with the

* Corresponding author at: Universidade Federal do Espírito Santo, Av. Marechal Campos, 1468, Maruípe, Vitória, ES, Brazil.
E-mail address: afaccini@gmail.com (Á.A. Faccini-Martínez).

recent serological evidence that suggests the circulation of SFGR species in the Colombian Orinoquia, we consider to recognize this region as a new endemic area for SFG Rickettsioses.

© 2016 King Saud Bin Abdulaziz University for Health Sciences. Published by Elsevier Limited. All rights reserved.

Case report

Spotted fever group (SFG) rickettsioses are actually considered as emerging and re-emerging zoonotic diseases, caused by pathogenic bacteria of the spotted fever group rickettsiae (SFGR), transmitted to human beings through tick bites [1]. In Colombia, to date, *Rickettsia rickettsii* has been the only species of the SFG identified in human cases as well as in *Amblyomma patinoi* ticks [2,3], being the central region (Department of Cundinamarca) and northwestern Colombia (Departments of Cordoba and Antioquia) known as endemic areas for such rickettsiosis [4–6]. Recently, serologic studies in human and animals conducted in Colombian Orinoquia (Departments of Arauca, Casanare, Guaviare, Meta and Vichada), showed a high seroprevalence against SFGR [7,8].

In June 2015, a 50-year-old male without previous medical history, was admitted to a hospital in Bogotá, Colombia, with two days of malaise and temperature of 39°C, associated to

generalized rash 24h after the onset of fever. He referred a work visit and outdoor activities in rural area of the municipality of Puerto Gaitán (Department of Meta, Eastern center region of Colombia) 15 days prior the onset of symptoms. He denied contact with animals, insect bites or contact with stagnant waters. Physical examination revealed good general condition, temperature of 38°C, heart rate of 95 beats/min, respiratory rate of 18 breaths/min, no conjunctival suffusion, oropharynx with enanthem, no lymphadenopathy, cardio-pulmonary exam without alterations, abdomen without visceromegalies, no meningeal signs, maculopapular rash on the trunk and extremities with involvement of palms and soles (Fig. 1, Panel A and B) and absence of inoculation eschar.

Initial blood analysis showed leukocytosis (13,970 cells/ μ L), neutrophilia (92.8%), thrombocytopenia (142,000 platelets/ μ L) and elevated transaminases (AST [99 U/L], ALT [118 U/L]), PCR (16 mg/L) and procalcitonin (2.1 ng/mL). The patient was hospitalized and started Ceftriaxone

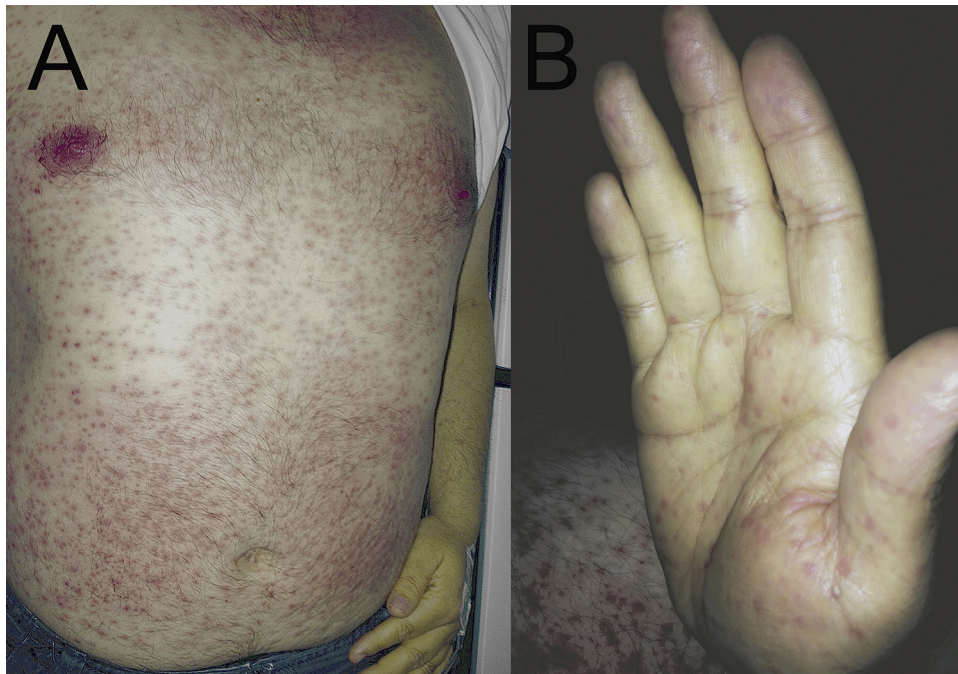


Figure 1 Probable case of spotted fever group rickettsial infection in a Colombian patient. Maculopapular rash on the trunk (A) and extremities with involvement of palms (B) and soles.

(2 g/day) after taking blood cultures and serologic tests for Dengue, Chikungunya, HIV, Syphilis (VDRL), CMV, EBV, Toxoplasma and viral hepatitis (A, B and C). On the second day of hospitalization the patient showed clinical deterioration and persistence of fever, associated to onset of dry cough, mild respiratory distress, abdominal pain and petechial lesions in lower limbs. Serology and blood cultures were negative. An increase of leukocytosis (21,540 cells/ μ L), neutrophilia (97%), transaminases (AST [138 U/L], ALT [134 U/L]), PCR (26 mg/L) and procalcitonin (9.9 ng/mL) was observed, with persistence of thrombocytopenia (98,000 cells/ μ L). The patient was transferred to the intensive care unit with supplementary oxygen, inotropic support and was assessed by the infectious diseases department, indicating the addition of Doxycycline (100 mg/every 12 h) and additional serologic tests on the suspicion of rickettsial infection. On the third day of hospitalization a biopsy of the skin lesions was performed, with histopathologic findings suggestive of nonspecific lymphohistiocytic vasculitis of small vessels. Seventy-two hours later the patient showed significant improvement in the respiratory pattern, clinical stability and absence of new fever peaks. After seven days of antibiotic treatment with Ceftriaxone plus Doxycycline, the patient was discharged with no evidence of new symptoms or sequels. Retrospectively, two serum samples collected during the acute phase (second day of hospitalization) and convalescent phase (15 days after the first sample) were evaluated in order to determine total antibodies by the Microagglutination Test against 27 pathogenic serovars of *Leptospira* spp. and IgM antibodies (fluorescein isothiocyanate-labeled goat anti-human IgM [Sigma, St. Louis, MO]) by indirect immunofluorescence assay (IFA) against SFGR (*R. rickettsii* antigen). Both serum samples were negative for *Leptospira* spp., however, there was four fold rise in titer against SFGR with titers of 1/128 and 1/512 for acute and convalescent phase samples, respectively. Additionally, in order to identify the responsible *Rickettsia* species by molecular methods, a PCR assay was performed for amplification of the *gltA* rickettsial gene from DNA extracted from paraffin samples of the patient's skin biopsy (QIAamp DNA FFPE Tissue Kit [Qiagen, CA, USA] was used according to the manufacturer's instruction); unfortunately the result was negative.

This case presents several features both clinical and paraclinical compatible with probable infection by SFGR [9]: (I) unspecific acute febrile syndrome associated to maculopapular rash with involvement of palms and soles and subsequent presence of

purpuric lesions associated with rapid clinical deterioration, with favorable evolution 72 h after the early treatment with Doxycycline; (II) leukocytosis with neutrophilia associated with thrombocytopenia and elevated transaminases; and (III) four fold rise in antibody titer against SFGR in paired samples by IFA test and presence of lymphohistiocytic vasculitis in the histopathologic findings. Regarding the latter, although skin biopsy is considered as an ideal sample for detection and molecular confirmation of the *Rickettsia* species, early treatment with Doxycycline prior to sampling can decrease the sensitivity of molecular methods [9]; situation that can explain the negative results of PCR in our case.

On the other hand, although there have not yet been published studies about molecular characterization of *Rickettsia* species in ticks of Meta department (likely area of the patient's infection), it was recently described the presence of *Amblyomma mixtum* ticks (known vector of *R. rickettsii* in Central America) in neighboring Departments of Meta [10]. With the foregoing, associated with the recent serological evidence that suggests the circulation of SFGR species in the Colombian Orinoquia [7,8], we consider to recognize this region as a new endemic area for SFG Rickettsioses.

Funding

No funding sources.

Competing interests

None declared.

Ethical approval

Not required.

References

- [1] Parola P, Paddock CD, Socolovschi C, Labruna MB, Medianikov O, Kernif T, et al. Update on tick-borne rickettsioses around the world: a geographic approach. *Clin Microbiol Rev* 2013;26:657–702.
- [2] Patino L, Afanador A, Paul JH. A spotted fever in Tobia, Colombia. *Am J Trop Med* 1937;17:639–53.
- [3] Faccini-Martínez ÁA, Costa FB, Hayama-Ueno TE, Ramírez-Hernández A, Cortés-Vecino JA, Labruna MB, et al. *Rickettsia rickettsii* in *Amblyomma patinoi* ticks, Colombia. *Emerg Infect Dis* 2015;21:537–9.
- [4] Hidalgo M, Orejuela L, Fuya P, Carrillo P, Hernandez J, Parra E, et al. Rocky Mountain spotted fever, Colombia. *Emerg Infect Dis* 2007;13:1058–60.

- [5] Hidalgo M, Miranda J, Heredia D, Zambrano P, Vesga JF, Lizarazo D, et al. Outbreak of Rocky Mountain spotted fever in Córdoba, Colombia. *Mem Inst Oswaldo Cruz* 2011;106:117–8.
- [6] Acosta J, Urquijo L, Díaz A, Sepúlveda M, Mantilla G, Heredia D, et al. Brote de rickettsiosis en Necoclí, Antioquia, febrero-marzo de 2006. *Informe Quincenal Epidemiológico Nacional* 2006;11:177–92.
- [7] Miranda JL, Sánchez L, Amaya K, Máttar S. Primera prueba serológica de *Rickettsia* sp. del grupo de la fiebre manchada en el departamento del Meta. *Biomedica* 2011;31:103–13.
- [8] Riveros-Pinilla DA, Acevedo L, Londoño AF, Góngora A. Antibodies against spotted fever group *Rickettsia* sp., in horses of the Colombian Orinoquia. *Rev MVZ Córdoba* 2015;20:5004–13.
- [9] Biggs HM, Behravesh CB, Bradley KK, Dahlgren FS, Drexler NA, Dumler JS, et al. Diagnosis and management of tick-borne rickettsial diseases: Rocky Mountain spotted fever and other spotted fever group rickettsioses, ehrlichioses and anaplasmosis—United States. *MMWR Recomm Rep* 2016;65:1–44.
- [10] Rivera-Páez FA, Labruna MB, Martins TF, Sampieri BR, Camargo-Mathias MI. *Amblyomma mixtum* Koch, 1844 (Acari: Ixodidae): first record confirmation in Colombia using morphological and molecular analyses. *Ticks Tick Borne Dis* 2016;7:842–8.

Available online at www.sciencedirect.com

ScienceDirect